

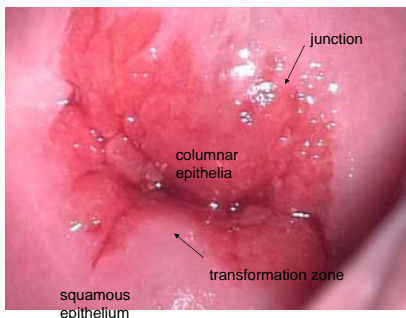
Colposcopy workshop intro Ljubljana 9.4.2010

Associate professor Pekka Nieminen M.D. Ph.D
Dept. Obst & Gyn, Helsinki University Hospital

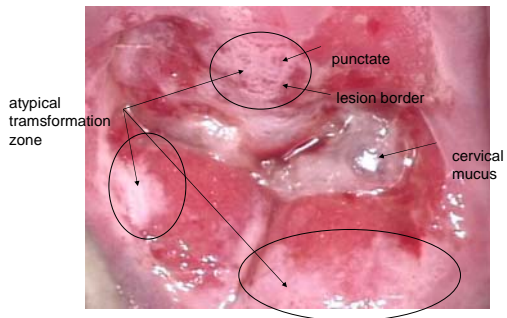
Aims

- To learn and evaluate colposcopy techniques as well as findings
- To adapt Reid Colposcopy Index (RCI) into routine colposcopy and teaching

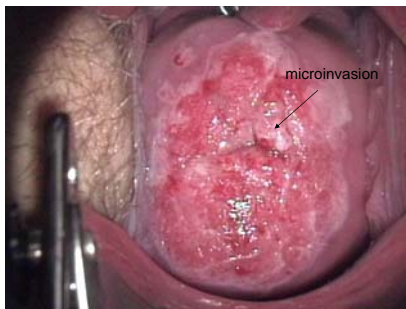
Normal colposcopic findings and nomenclature



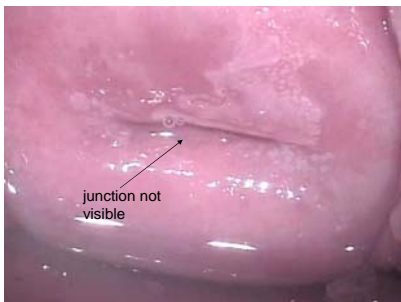
Atypical transformation zone



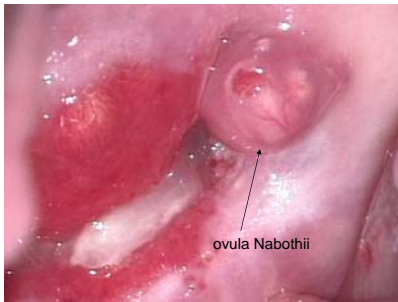
Invasive carcinoma, suspicion



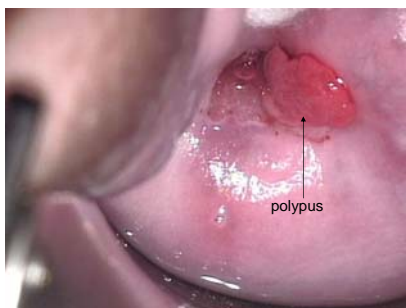
Undiagnosical colposcopy



Ovula Nabothii



Cervical polyp



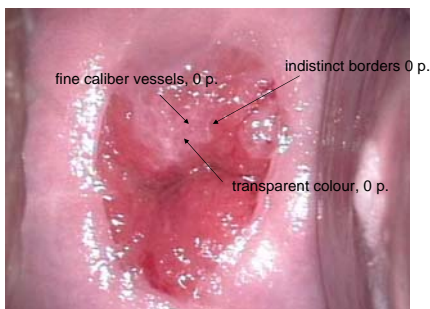
Reid Colposcopic index

	0 points	1 point	2 points
Borders of the Lesion	Flat lesion, indistinctive borders, feathe rlike, angular, geographic, satellites	Regular, symmetric, straight borders	Peeling, lesion indide lesion
Color	Transparent whitenes, snow white	Intermediate whitenes	Opaque, strong whiteness, yellowish, grey
Vessels	Fine caliber punctation, mosaicism	No vessels	Coarse caliber punctation, mosaicism

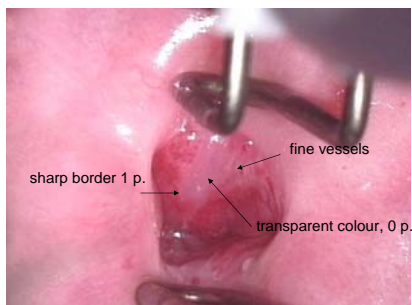
Reid Colposcopic index

RCI points	Histology
0-2	Normal, immature metaplasia, HPV atypia
3-4	CIN 1/dysplasia levis, CIN 2/dysplasia moderata
5-6	CIN 2, CIN 3, Ca in situ

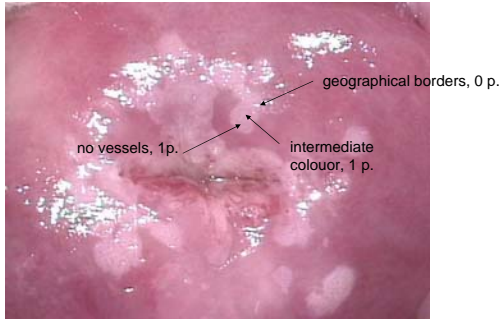
RCI 0 points, immature metaplasia



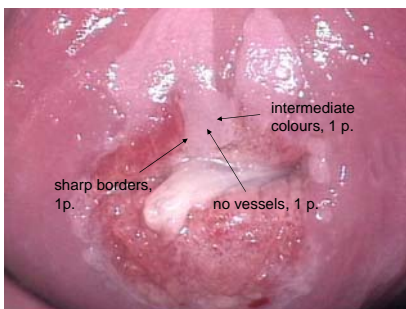
RCI 1 point, immature metaplasia



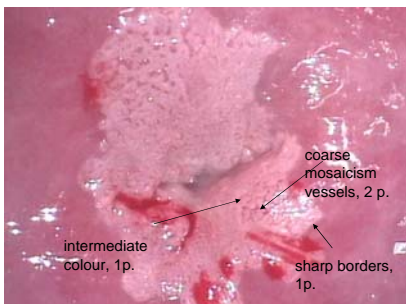
RCI 2 points, atypia condylomatosa/CIN1



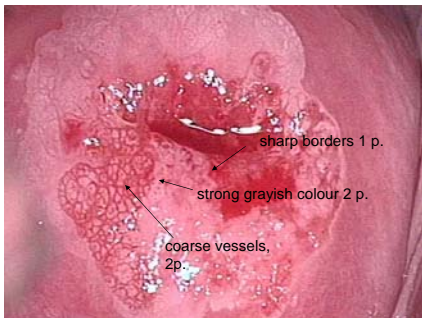
RCI 3 points, mild dysplasia/ CIN1



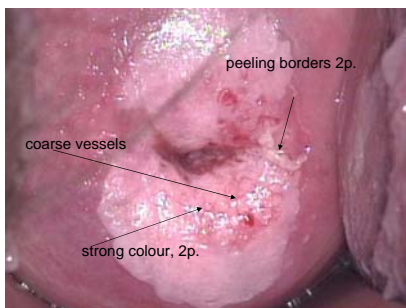
RCI 4 points, dysplasia moderata/ CIN 2



RCI 5 points, dysplasia gravis/CIN3



RCI 6 points, dysplasia gravis/CIN3



If you want to do web based colposcopies, go to

- http://www.terveysportti.fi/kotisivut/sivut.koti?p_sivusto=640&p_navi=58215&p_sivu=58053
- 16 interactive cases
